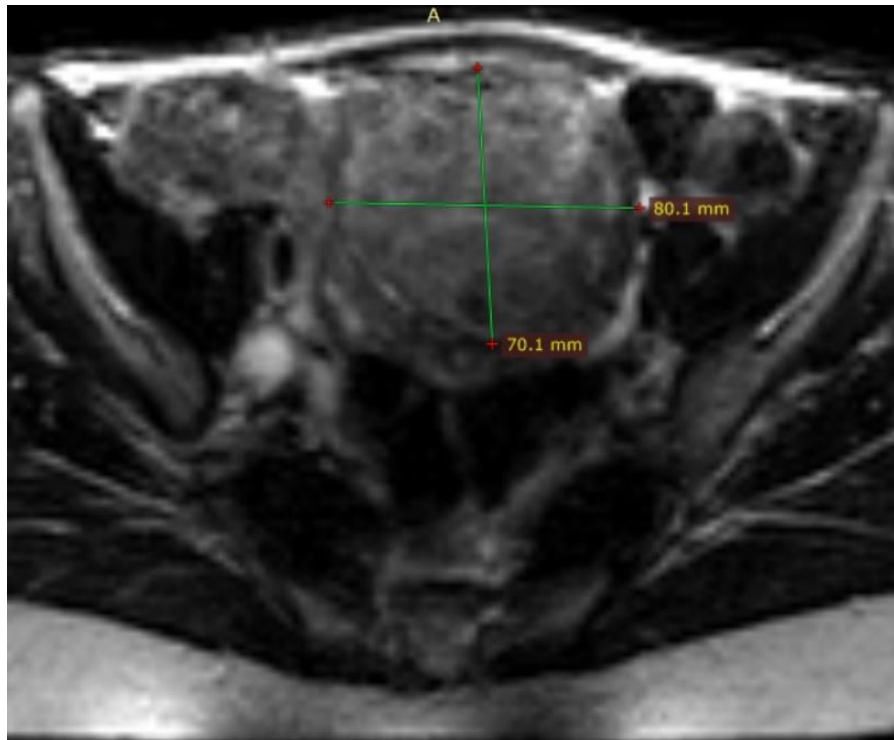
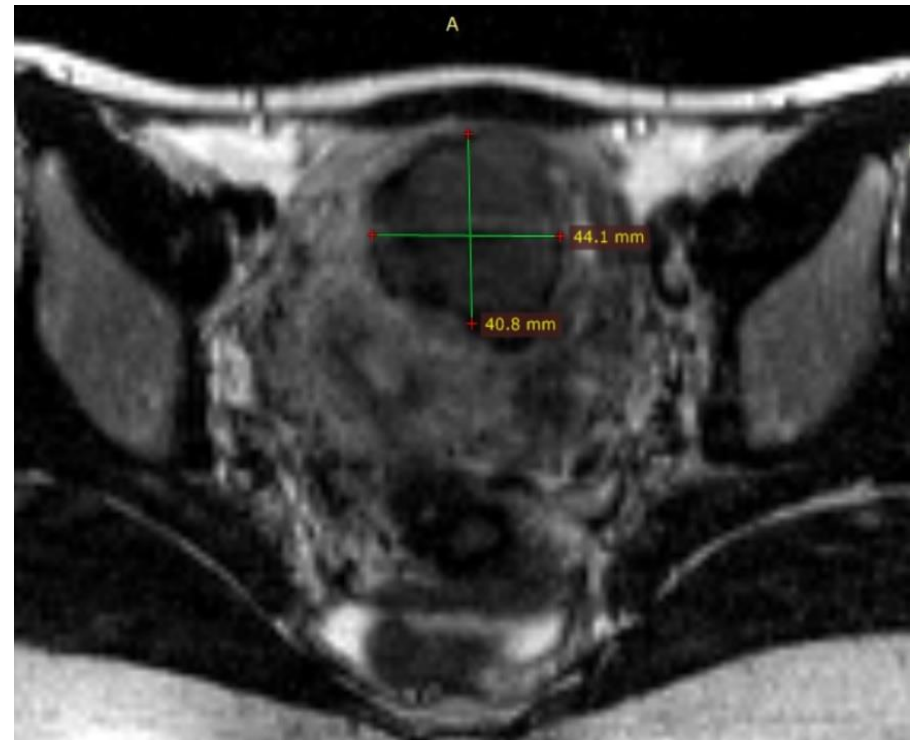


# Follow-up 6 months after the ablation

**before the HIFU ablation**

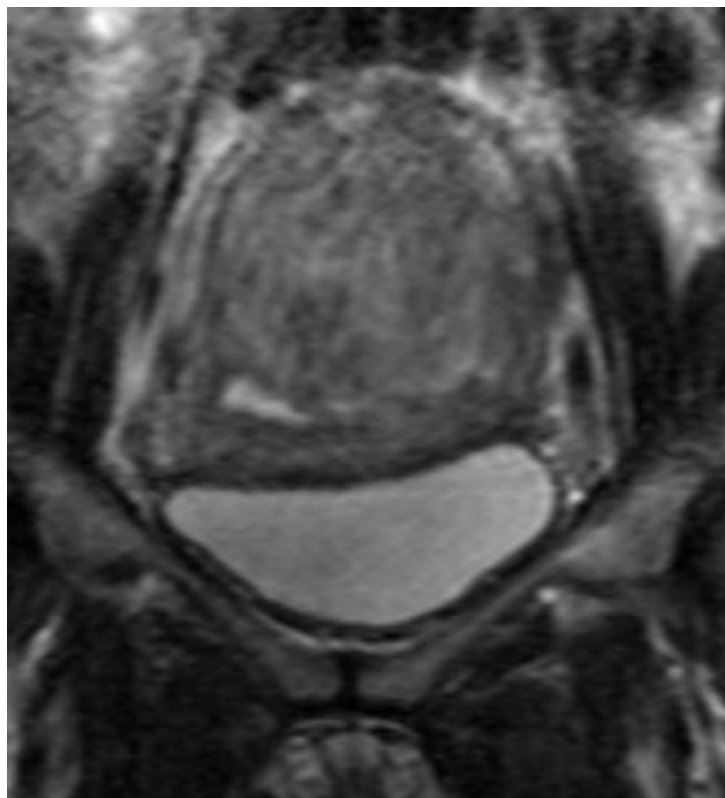


**6 months after the HIFU ablation**

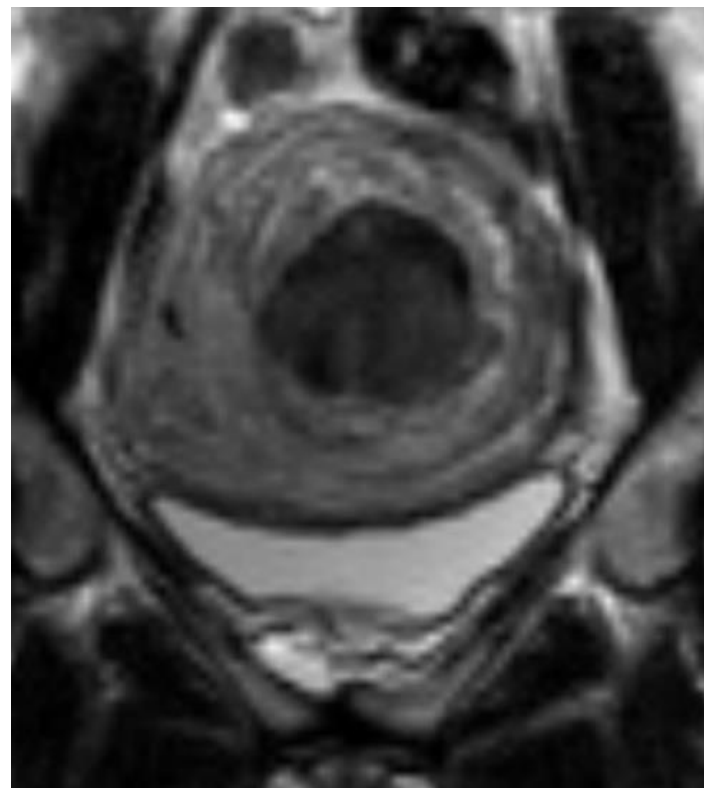


# Follow-up 6 months after the ablation

Преди ХАЙФУ



6 месеца след ХАЙФУ



A patient with uterine fibroid of 80/70 mm in size underwent a session of HIFU therapy in the “Saint Marina” HIFU Center. Six months after the procedure her MRI scans visualized the zone of necrosis of 44/40 mm, which testified for almost 50% reduction of the nodule. It is expected that the necrotic zone, respectively the fibroid itself, will continue further to reduce in size. The myoma related symptoms disappeared two months after her HIFU treatment.